

Susan Rogers, Esq.
Executive Director



J. Kevin Stitt
Governor

**Board of
Dentistry**

OKLAHOMA STATE BOARD OF DENTISTRY

2920 N Lincoln Blvd, Ste B

Oklahoma City, Oklahoma 73105

Phone 405/522-4844 Fax 405/522-4614

Dr. Michael Howl
Tulsa, Oklahoma
President

SB 754 Hygiene Advanced Procedures Information

Dr. Bobby Carmen
Norman, Oklahoma
1st Vice- President

As of July 1, 2023, there will be four additional advanced procedures available for Oklahoma Hygienists to apply for pursuant to the passage of legislation this year. To qualify for any of these advanced procedures, you will be required to complete educational requirements in a program **APPROVED BY THE BOARD.**

Dr. Erin Roberts
Enid, Oklahoma
2nd Vice President

However, even though the statute will go into effect on July 1st, 2023, the rules also must go into effect which delineate out the educational requirements. The Governor signed the legislatures approval of the rules on May 31st. The final rules are required to be published prior to going into effect which at the earliest date will not be before September 1, 2023.

Dr. Krista Jones
Edmond, Oklahoma
Secretary/Treasurer

Dr. Jeff Lunday
Newcastle, Oklahoma

The Board will NOT approve any courses for advanced procedures until the rules are in effect. Any entity that wishes to submit material or information regarding a course may do so as early as June 7th as this will be a discussion item on the June 16th 2023 Board Agenda.

Dr. Brant Rouse
Ft. Gibson, Oklahoma

Chief Phil Cotten
(Retired)
Norman, Oklahoma

The new advanced procedures are:

Dr. Lisa Nowlin
Elk City, Oklahoma

1. Neuromodulator Administration,
2. Therapeutic Use of Lasers,
3. Vaccinations, Venipuncture and Phlebotomy.
4. Elder Care and Public Health Advanced Procedures
(Supervision may be done by teledentistry)

Dr. Stan Crawford
Grove, Oklahoma

Charles Floyd, Esq.
Tulsa, Oklahoma

Rachel Ostberg, RDH
Bartlesville, Oklahoma

There are important requirements to be eligible to apply for an advanced procedure for each of these to be aware of:

Stephen McCaleb, Esq.
Judicial Counsel

A hygienist wishing to obtain the Neuromodulator Administration advanced procedure must:

- (1.) already hold the administration of nitrous and local anesthesia advanced procedures
- (2.) have at least two (2) years of hygiene experience
- (3.) maintain malpractice insurance (this will have to be with your application)
- (4.) ALL procedures must be done under **DIRECT OR INDIRECT SUPERVISION OF YOUR DENTIST.**
- (5.) the hygienist must also submit with the application a statement certifying each neuromodulator and dermal filler they inject will be approved for the use in dentistry by the FDA.



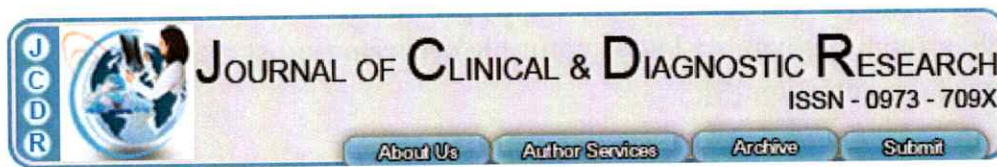
A hygienist wishing to obtain the Therapeutic Use of Lasers advanced procedure must first complete an educational program that has been pre-approved by the Board that is a minimum of 8 hours. Hygienists may only use lasers under direct or indirect supervision of a dentist and the use is limited to soft tissue decontamination, sulcular bacterial reduction and tissue disinfection.

A hygienist wishing to obtain the Elder Care and Public Health Advanced Procedure must have at least two years of hygiene experience. A hygienist with a prior Board action within the previous five years shall not be eligible for this advanced procedure.

There are additional rules and guidelines related to these advanced procedures that will be forthcoming as we process through these changes. It is important for all licensees to stay up to date with the current updates in the statutes and rules as many currently in effect will apply separately to these procedures. For example, the supervising dentist must have and maintain a patient record on every patient for any treatment including a patient receiving only Neuromodulator Administration (botox). Please review the attached medical journal articles regarding the uses of botox in dentistry and PRP.

In the past seven years, there have been more advances in dentistry and medical technology than in the previous twenty years. The Board is trying to stay cognizant of these changes and allow for new technology for the dentists that want to do it. That does not mean all dentists will want their hygienists doing any of the additional advanced procedures that will be available.

If you have any questions or would like to submit a course for review, please contact Deputy Director, Jeff Puckett at Jeff.Puckett@dentistry.ok.gov.



[J Clin Diagn Res](#). 2014 Dec; 8(12): ZE25–ZE29.

PMCID: PMC4316364

Published online 2014 Dec 5. doi: [10.7860/JCDR/2014/11624.5341](https://doi.org/10.7860/JCDR/2014/11624.5341)

PMID: [25654058](https://pubmed.ncbi.nlm.nih.gov/25654058/)

BOTOX: Broadening the Horizon of Dentistry

[Pranav Nayyar](#),¹ [Pravin Kumar](#),² [Pallavi Vashisht Nayyar](#),³ and [Anshdeep Singh](#)⁴


Abstract

Botox has been primarily used in cosmetic treatment for lines and wrinkles on the face, but the botulinum toxin that Botox is derived from has a long history of medically therapeutic uses. For nearly 13 years, until the introduction of Botox Cosmetic in 2002, the only FDA-approved uses of Botox were for crossed eyes (strabismus) and abnormal muscle spasms of the eyelids (blepharospasm). Since then botulinum A, and the seven other forms of the botulinum toxin, have been continuously researched and tested. Botox is a neurotoxin derived from *bacterium clostridium botulinum*. The toxin inhibits the release of acetylcholine (ACH), a neurotransmitter responsible for the activation of muscle contraction and glandular secretion, and its administration results in reduction of tone in the injected muscle. The use of Botox is a minimally invasive procedure and is showing quite promising results in management of muscle-generated dental diseases like Temporomandibular disorders, bruxism, clenching, masseter hypertrophy and used to treat functional or esthetic dental conditions like deep nasolabial folds, radial lip lines, high lip line and black triangles between teeth.

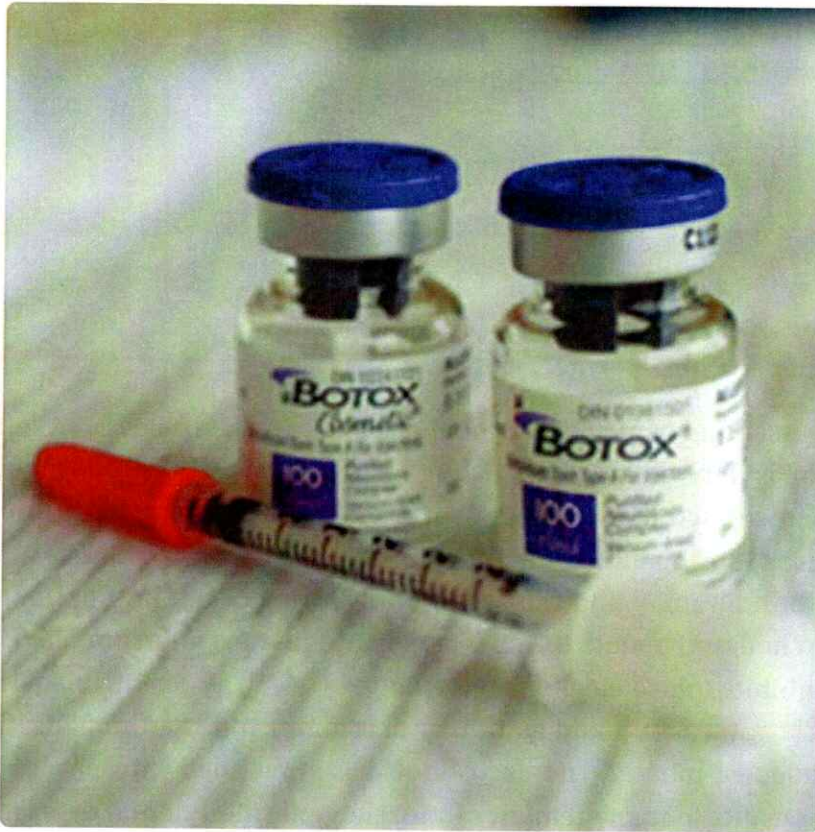Keywords: Black triangles, Botulinum toxin A, Bruxism, Gummy smile, Hyperfunction

Introduction

Many of us think of Botox primarily as a cosmetic treatment for lines and wrinkles on the face, but the botulinum toxin that Botox is derived from has a long history of medically therapeutic uses such as in cervical dystonia, hyperhidrosis, strabismus and blepharospasm. Botox has now been increasingly used in dentistry as well due to its therapeutic uses in treatment of certain oral conditions. The Dental Quality Assurance Commission (DQAC) of Washington has released an interpretive statement effective July 26, 2013, which now affirms the ability of general dentists to use Botox and dermal fillers when “used to treat functional or aesthetic dental conditions and their direct aesthetic consequences and the treating dentist has appropriate, verifiable training and experience.” Similarly, Michigan board of dentistry and New Jersey state board also approves the use of Botox and dermal fillers by general dentists. Botulinum toxin is a protein and neurotoxin produced by the *bacterium Clostridium botulinum* [1] [Table/Fig-1] [2]. Currently, seven bo-



tulinum neurotoxin serotypes (A, B, C1, D, E, F, and G) produced by *Clostridium botulinum*, are recognized. Although botulinum toxin is a lethal, naturally occurring substance, it can be used as an effective and powerful medication [3].



[Table/Fig-1]:

Commercially available Botulinum Toxin A as Botox (Allergan) [2]

Feedback

Three forms of botulinum toxin type A (Botox, Dysport and Xeomin) and one form of botulinum toxin type B (MyoBloc) are available commercially for various cosmetic and medical procedures.

Each vial of BOTOX contains-

1. 100 Units (U) of *Clostridium botulinum* type A neurotoxin complex,
2. 0.5 milligrams of Albumin Human,
3. And 0.9 milligrams of sodium chloride in a sterile, vacuum-dried form without a preservative.

Botulinum toxin type A can be used in following dental conditions:-

1. Temporomandibular joint disorders
2. Bruxism
3. Oromandibular dystonia

4. Mandibular spasm
5. Pathologic clenching
6. Dental implant and surgery
7. Gummy smile
8. Masseteric hypertrophy

Mechanism of Action

Injecting overactive muscles with minute quantities of botulinum toxin type-A results in decreased muscle activity. Botulinum toxin type-A inhibits the exocytosis of acetylcholine on cholinergic nerve endings of motor nerves [4], as it prevents the vesicle where the acetylcholine is stored from binding to the membrane where the neurotransmitter can be released. Botulinum toxin achieves this effect by its endopeptidase activity against SNARE proteins, which are 25-kd synaptosomal associated proteins that are required for the docking of the ACH vesicle to the presynaptic membrane [5]. Botulinum toxin type-A thus blocks the release of acetylcholine by the neuron. This effectively weakens the muscle for a period of three to four months [6].

Temporomandibular Joint Disorders

Temporomandibular disorder (TMD) is a term used to describe a number of diseases affecting masticatory function, which may include true pathology of the temporomandibular joint as well as masticatory muscle dysfunction [7,8]. TMD manifests with facial pain, joint sounds, headache, periauricular pain, neck pain, and/or decreased jaw excursion. The majority of TMD cases include a myogenic component [9,10] and muscular spasticity secondary to bruxism, external stressors, oromandibular dystonia, and psychomotor behaviours are common aetiologic factors of TMD [11].

TMD caused by excessive biting forces has conventionally been treated with intraoral appliances, occlusal adjustments, dental restoration, and/or surgery. These techniques are invasive, irreversible, and expensive for the majority of patients.

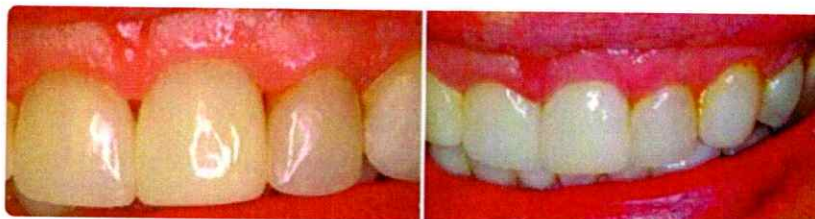Techniques currently employed for aesthetic, conservative restorations may not withstand the parafunctional forces continually applied by some patients. Thus, many of these treatment options are not ideal for all patients, and muscular relaxation with botulinum toxin A is a viable alternative. When a muscle relaxant is used with the muscles of mastication, this clenching reflex can be reduced or eliminated [12]. Because a very small percentage of available force is required to masticate food, a slight relaxation of muscle function reduces bruxing and is usually insufficient to affect chewing and swallowing [13].

Dentofacial Aesthetics

Botox and Dermal fillers can provide immediate volume to areas around the mouth, such as the nasolabial folds, marionette lines, and lips to create the proper lip lines, smile lines, and phonetics. Dermal fillers, such as Juvéderm® and Restylane®, are volumizers—or plumpers—that fill out lips

and static folds in the face caused by loss of collagen and fat.

Botox can also be used in a lip deformity where the lip rises more on one side than the other. It has to be injected at a specific site controlling where the lip goes and how much of it is raised and where and finally, the dreaded “black triangles” which is one of the most challenging aesthetic problems, for which there are very limited successful treatment options. Food particles accumulate in the space and create aesthetic issues. Dermal fillers can be injected into the interdental papilla to plump it and close the interdental space [Table/Fig-2][14]. Treatment outcome usually last for eight months or longer—at which point the treatment needs to be repeated.



[Table/Fig-2]:

Black triangles between the teeth can be filled up by Botulinum toxin A [14]

Bruxism

Botulinum neurotoxin has also shown promise in alleviating the symptomatology of bruxism. One of the earliest reports on use of botulinum toxin type A for bruxism was by Van Zandijcke and Marchau [15], who described the successful treatment of a brain-injured patient with severe bruxism with 100 U of a botulinum toxin type A injections to the temporalis and masseter muscles

Dental Implants and Surgery

Overloading of the muscles of mastication can prevent or impede osseointegration of implants and/or fracture callus formation [16,17]. The muscular relaxation achieved with botulinum toxin type A injections to the masticatory muscles can be therapeutically beneficial by allowing implants better unimpeded osseointegration and fracture healing in a more stable environment.

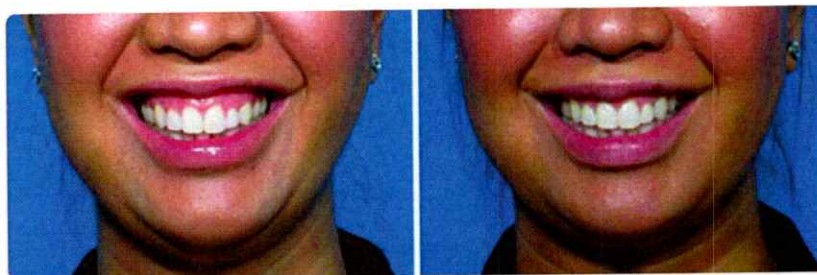Kayikvioglu and colleagues [17] conducted a small open-label study to prospectively examine the use of botulinum toxin type A as an adjunct to zygomatic fracture fixation surgery, in an attempt to reduce the number of fixation sites and to prevent dislocation of the zygomatic bone. Five male patients with zygomatic bone fractures were injected with 100 U of botulinum toxin type A into the masseter muscle of the fractured side. Patients were then operated on 12 to 48 h after the injection and EMG confirmation of muscle denervation. The temporary paralysis of the masseter muscles allowed for fewer miniplate and/or microplate insertions in all patients, and resulted in

no complications related to either the botulinum toxin injections or surgical procedures [17]. Kayikvioglu's group also found similar benefits of adjunct botulinum toxin treatment for surgical reduction of mandibular and condylar bone fractures [17].

Gummy Smile

The display of excessive gingival tissue in the maxilla upon smiling, or "gummy smile," is both an oral hygiene and cosmetic issue with no simple remedy. Excessive gum exposure is frequently attributable to over-contraction of the upper lip muscles, particularly the levator labii Superioris alaeque nasi. Although several surgical techniques have been reported in the literature for correction of hyperfunctional upper lip elevator muscles, such as the Rubinstein and Kostianovsky [18], Miskinyar [19], and Rees and LaTrenta [20] techniques, they are not routinely used to treat gummy smile [21]. In general, the most common surgical corrections currently used are the LeFort I maxillary osteotomies with impaction for skeletal vertical maxillary excess, and gingivectomies for delayed passive dental eruption with excessive gingival display [21,22].

Botulinum toxin should be injected in small, carefully titrated doses to limit muscular over-contraction of upper lip, thus reducing exposure of the upper gums when smiling. Hwang et al., at Yonsei University College of dentistry, Seoul, Korea have proposed a injection point for botulinum toxin and named it as Yonsei point [23]. It is basically a point located at the centre of triangle formed by levator labii superioris, levator labii superioris alaeque nasi and zygomaticus minor [Table/Fig-3] [24]. A dose of 3U is recommended at each injection site.



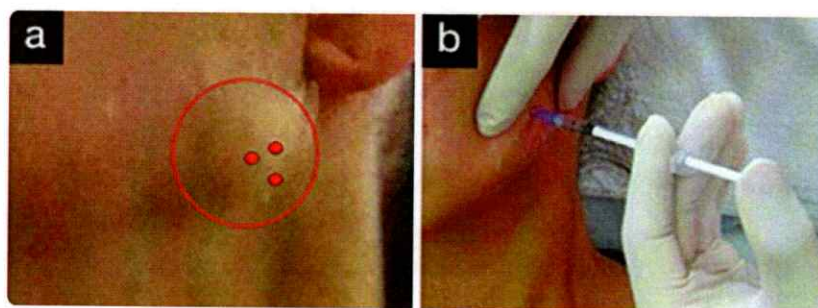
[Table/Fig-3]:

Botulinum toxin A is being used in treating patients with gummy smile [24]

In a small open-label trial, five patients with excessive gingival display resulting from hyperfunctional upper-lip elevator muscles were treated with Botox injections under electromyographic guidance [25]. Patients received one 0.25 U per muscle bilaterally into the levator labii superioris, levator labii Superioris alaeque nasi, and at the overlap areas of the levator labii superioris and zygomaticus minor muscles. All of the patients were pleased with the results and the effective increase in upper-lip length upon smiling averaged 124.2% [25]. The duration of effect ranged from 3 to 6 months, and no adverse effects were reported or observed. However, the improvement is temporary and must be repeated every six months to one year.

Masseteric Hypertrophy

Patients who are chronic jaw clenchers frequently present with masseter hypertrophy [26,27]. The increased size of these muscles is evident in the patient's facial appearance which is often substantially altered. The jaw appears swollen and misshapen. The common treatment before botulinum toxin was surgical resection [28], which results in substantial contracture. In several small but well-documented clinical trials, the injection of small aliquots (e.g., 30 U per side) of Botox into the masseter muscles resulted in a sustained reduction of masseter hyperactivity [26,27,29,30] [Table/Fig-4a,b] [31]. Over time, in most patients, reduction in masseter hyperactivity has been found to yield a concomitant reduction in gross masseter size (maximum reduction 35.4%) [27]. If the underlying pathology responsible for the hyperactivity is resolved, the reduction in masseter hypertrophy remains an enduring effect even after Botox applications have ceased [29,30].



[Table/Fig-4]:

(a) Location for botulinum toxin A injection in hypertrophied masseter muscle (b) botulinum toxin A injection of masseteric hypertrophy [31]

Mandibular Spasm

When the mandibular closing musculature remains semicontracted or in spasm, mouth opening becomes limited. This type of muscular spasm places limitations on completing the basic oral hygiene necessary to prevent oral disease [32]. Other impairments can include: restrictions on dental treatment, difficulty with eating and diminished oral utility (a broad spectrum of oral functions are impaired by restricted opening and the contraction of bite radius). Botulinum toxin treatment to the masticatory musculature diminishes the effects of hyperfunctional or spastic muscles [33].

Oromandibular Dystonia

Oromandibular dystonia (OMD) is a movement disorder characterized by involuntary spasms and muscle contractions. It manifests as distorted oral position and function resulting in difficulty in speaking, swallowing, and eating. Although it is a neurologic disorder, it is included as a subset of TMD because of its involvement of the masticatory apparatus [34]. Most of the reported literature

on OMD has been open-label studies, but all have reported improvement with botulinum toxin injections [35–39]. The largest study to date was a prospective open-label conducted by Tan and Jankovic that treated 162 patients with OMD over a 10-year period [39]. Botulinum toxin type A was injected into the masseters and/or the submental is complex. Improvement in function for chewing and speaking was reported in 67.9% of the patients, and mean duration of clinical improvement was 16.4 ± 7.1 wk [38].

Pathologic Clenching

Excessive forces created by parafunctional clenching impede healing and reattachment of gum and bone in the mouth after trauma [40]. Botulinum toxin type A limits the muscle contraction, and this reduction in clenching intensity will allow traumatized tissue to heal. Because parafunctional clenching contributes to periodontal trauma, botulinum toxin type A can limit clenching before and after periodontal surgery to improve healing. Further, in this application, the use of a splint is often contraindicated because the teeth should be functional during healing, so Botulinum toxin acts as a pharmaceutical splint.

Orthodontic treatments on patients who are clencher or have a deep or crossed bite are prolonged if the vertical component of muscular force is greater than the force of the fixed or removable appliance. These cases often require the use of removable functional retainers in combination with regular fixed braces in an attempt to control the component of vertical force [41]. With the use of botulinum toxin, orthodontic treatment time can be reduced, and patients would be far more comfortable and functional (eating, speaking, swallowing).

Other Uses

- Sialorrhea:** This toxin also blocks the release of acetylcholine at the cholinergic synapses of the autonomic nervous system; thus, this toxin can block cholinergic parasympathetic secretomotor fibers of the salivary gland. Hence, botulinum toxin has been tested in some autonomic disease, such as achalasia, hyperhidrosis and gustatory sweating (Frey syndrome) [42]. Lim and Choi [43] have reported that injection of botulinum toxin type A is a highly effective and relatively safe primary method of treatment for an acute postparotidectomy salivary fistula that, if treated with conventional pressure dressings, takes long to subside.
- Trigeminal Neuralgia:** BOTOX 25–75 U injected into pericranial muscles relieves headache by relaxing the over active muscles by blocking nerve impulses that trigger contractions. According to Elcio, excruciating pain associated with inflammation of the trigeminal nerve of the head and face can be substantially relieved by injections of BOTOX [44].
- Retraining Muscles During Orthodontic Treatment:** Botox can be used to prevent relapse of orthodontic treatment in case of patients with stronger muscle activity such as that of mentalis muscle. Botox can be used to reduce the intensity of the muscle post treatment and over time, the muscle may be retrained to a more physiological movement.
- Botox can be used in patients with a new denture especially if the patient has long history of edentulousness and has decreased vertical dimension.

5. Higher doses of botulinum toxin type A may potentially be used as a pharmaceutical splint, limiting muscle contraction before resetting and during rehabilitation after fracture of a facial bone (e.g., fractured mandibular condyle).
6. Botulinum toxin type A can be used to verify whether the pain is muscular or pulpal (e.g., complex toothache) in origin in patients with chronic intermittent toothache [45]. For example, muscle pain from the anterior temporalis is often referred to the teeth. This should be treated before any major irreversible dental treatments are undertaken. In this context, the use of botulinum toxin type A is both prophylactic as well as diagnostic.

Contraindications

Patients should not be treated or treated with extreme caution who are [46]:

- Psychologically unstable or who have questionable motives and unrealistic expectations.
- Dependent on intact facial movements and expressions for their livelihood (e.g. actors, singers, musicians and other media personalities).
- Afflicted with a neuromuscular disorder (e.g. myasthenia gravis, Eaton-Lambert syndrome).
- Allergic to any of the components of BTX-A or BTX-B (i.e. BTX, human albumin, saline, lactose and sodium succinate).
- Taking certain medications that can interfere with neuromuscular impulse transmission and potentiate the effects of BTX (e.g. aminoglycosides, penicillamine, quinine, and calcium blockers).
- Pregnant or lactating (BTXs are classified as pregnancy category C drugs)

Discussion

Botox is a safe, conservative, non surgical, reversible, minimally invasive treatment modality to achieve cosmetic results. Training is absolutely necessary for dentists to administer injections, but learning curve is very short, because dentists can already achieve profound anaesthesia in the orofacial region, thus making patient more comfortable and at ease. Botulinum toxin A is kept frozen (2–4°C) in a vial until it is ready to use. The drug is put into solution, following manufacturer's guidelines, by adding normal saline (preservative-free 0.9% saline solution). Once prepared it should be used within four hours. The preferred syringe is a calibrated 1.0-mL tuberculin syringe, and the needle selected for injection usually is between 26 and 30 gauge. Skin preparation involves alcohol wipes and dry sterile gauze sponges. Aspiration before injection is recommended to avoid involuntary deposition of toxin into the facial arteries. Botulinum Toxin A achieves close to immediate results in one short appointment, but the results are not permanent and last for 6 months, with a range of 4-8 months [47]. Botulinum Toxin needs to be administered 2-3 times a year depending upon the declination of its effect. The therapeutic effects of Botulinum toxin A first appear in 1 to 3 d, peak in 1 to 4 wk, and decline after 3 to 4 mnth [48]. At the cellular level, 3 to 4 wk after a single injection of Botulinum toxin A in mice, there is sprouting of new processes along the nerve axon, with formation of multiple synapses with the muscle and up regulation of the muscle nicotinic receptors. Subsequently, the neuronal sprouts undergo regression and the original synaptic connection is restored, with restoration of the original neuromuscular junc-



tion [46,49]. Therefore, Botulinum toxin injections are needed to be administered 2-3 times a year, thereby increasing the cost factor to slightly higher level. Injections are spaced out for a minimum of three months to minimize the risk of antibody formation to the protein, which would prevent BOTOX from working the subsequent time [45]. Mild stinging, burning or pain with injection, edema and erythema around injection site are the localized adverse effects which are of limited duration. The potential adverse effects of botulinum toxin in oromandibular disorders include facial nerve palsy, pain at the injection site, flu-like symptoms, non-targeted muscle weakness, dysphagia, and hematoma. These complications are generally transient, and resolve within a couple of weeks. Hands-on training is essential in learning proper techniques of administration and intertwining them with dental treatment plans. With proper training, dentists are usually more proficient than any of other healthcare professionals in providing these treatments to patients, both for dental and cosmetic needs. The American Academy of Facial Aesthetics is conducting more than 50 local courses a year, has trained more than 6,000 dental professionals from 48 states and 28 countries through comprehensive hands-on live patient two-day facial aesthetic training sessions with Botox and dermal fillers [50]. The Indian Academy of Facial Aesthetics (IAOFE) in conjunction with the American Academy of Facial Aesthetics (AAFE) is also offering Botox and dermal fillers training course for dentists and physicians [51].

Conclusion

BOTOX has important clinical uses as an adjunct therapy in temporomandibular joint (TMJ) and bruxism cases, and for patients with chronic TMJ and facial pain. BOTOX is also used to complement aesthetic dentistry cases, as a minimally invasive alternative to surgically treating high lip-line cases, for denture patients who have trouble adjusting to new dentures, periodontal cases, gummy smiles, lip augmentation, and also for orthodontic cases where retraining of the facial muscles is necessary. However, much more is still to be discovered before its routine use in dentistry for various conditions. There are still many dental conditions which require FDA approval to be treated by botulinum toxin. Botulinum toxin has no doubt broadened the horizon of dentistry and is persuading dentists all over the world to bring it into their clinical practices.



Notes


Financial or Other Competing Interests

None.

References

- [1] Montecucco C, Molgò J. Botulinum neurotoxins: revival of an old killer. *Current Opinion in Pharmacology*. 2005;5(3):274-79. [[PubMed](#)] [[Google Scholar](#)]
- [2] <http://www.kencomerdds.com/botox.html>
- [3] Barbano Richard. Risks of erasing wrinkles: Buyer beware! *Neurology*. 2006;67(10):E17-18. [[PubMed](#)] [[Google Scholar](#)]

- [4] Meunier FA, Schiavo G, Molgo J. Botulinum neurotoxins: from paralysis to recovery of functional neuromuscular transmission. *J Physiol (Paris)* 2002;96(1-2):105-13. [[PubMed](#)] [[Google Scholar](#)]
- [5] Aoki KR. Evidence for antinociceptive activity of botulinum toxin type A in pain management. *Headache*. 2003;43(Suppl 1):S9-15. [[PubMed](#)] [[Google Scholar](#)]
- [6] Edwards, Michael (2006). "Anal fissure". Dumas Ltd. Retrieved August 21, 2010
- [7] Bentsianov BL, Francis A, Blitzer A. Botulinum toxin treatment of temporomandibular disorders, masseteric hypertrophy, and cosmetic masseter reduction. *Operative Techniques in Otolaryngology-Head and Neck Surgery*. 2004;15(2):110-13. [[Google Scholar](#)]
- [8] Olivo S, Bravo J, Magee DJ, et al. The association between head and cervical posture and temporomandibular disorders: A systematic review. *J Orofac Pain*. 2006;20(1):9-23. [[PubMed](#)] [[Google Scholar](#)]
- [9] Schwartz M, Freund B. *Botulinum Toxin A Therapy for Temporomandibular Disorders*. Philadelphia, Pa: Lippincott Williams & Wilkins; 2002. [[Google Scholar](#)]
- [10] Schwartz M, Freund B. Treatment of temporomandibular disorders with botulinum toxin. *Clin J Pain*. 2002;18(6 Suppl):S198-203. [[PubMed](#)] [[Google Scholar](#)]
- [11] Castenada R. *Temporomandibular Disorders*. Philadelphia, Pa: Saunders; 1992. Occlusion. In: Kaplan A, Assael L (eds) [[Google Scholar](#)]
- [12] Gobel H, Heinze A, Heinze-Kuhn K. Botulinum Toxin A is effective in cases of oromandibular dysfunction even if previous bite splint therapy has proved unsuccessful. *Cephalalgia*. 2001;514-15. [[Google Scholar](#)]
- [13] Freund B, Schwartz M, Symington JM, et al. The use of botulinum toxin for the treatment of temporomandibular disorders: Preliminary findings. *J Oral Maxillofac Surg*. 1999;57(8):916-21. [[PubMed](#)] [[Google Scholar](#)]
- [14] <http://www.dentaltown.com/dentaltown>
- [15] Van Zandijcke M, Marchau MM. Treatment of bruxism with botulinum toxin injections. *J Neurol Neurosurg Psychiatry*. 1990;53(6):530. [[PMC free article](#)] [[PubMed](#)] [[Google Scholar](#)]
- [16] Nishimura K, Itoh T, Takaki K, et al. Periodontal parameters of osseointegrated dental implants: A four-year controlled follow-up study. *Clin Oral Implants Res*. 1997;8(4):272-78. [[PubMed](#)] [[Google Scholar](#)]
- [17] Kayikvioglu A, Erk Y, Mavif E, et al. Botulinum toxin in the treatment of zygomatic fractures. *Plast Reconstr Surg*. 2003;111(1):341-46. [[PubMed](#)] [[Google Scholar](#)]
- [18] Rubenstein A, Kostianovsky A. Cosmetic surgery for the malformation of the laugh: original technique. *Prensa Med Argent*. 1973;60:952. [[Google Scholar](#)]
- [19] Miskinyar SA. A new method for correcting a gummy smile. *Plast Reconstr Surg*. 1983;72:397-400. [[PubMed](#)] [[Google Scholar](#)]
- [20] Rees T, LaTrenta G. The long face syndrome and rhinoplasty. *Persp Plast Surg*. 1989;3:116. [[Google Scholar](#)]
- [21] Polo M. Botulinum toxin type A in the treatment of excessive gingival display. *Am J Orthod Dentofacial Orthop*. 2005;127(2):214-18. [[PubMed](#)] [[Google Scholar](#)]
- [22] Amin V, Amin V, Swathi, Jabir A, Shetty P. Enhancing the smile with Botox-case report. *Global Journal of Medical Research*. 2013;13(2):14-18. [[Google Scholar](#)]



- [23] Hwang, et al. Surface anatomy of the lip elevator muscles for the treatment of gummy smile using botulinum toxin. *Angle Orthod.* 2009;79(1):70–77. [[PubMed](#)] [[Google Scholar](#)]
- [24] <http://www.vancouverlaser.com/procedures-treatments/botox-before-after-photos-05/>
- [25] Polo M. Botulinum toxin type A in the treatment of excessive gingival display. *Am J Orthod Dentofacial Orthop.* 2005;127(2):214–18. [[PubMed](#)] [[Google Scholar](#)]
- [26] Kim HJ, Yum KW, Lee SS, et al. Effects of botulinum toxin type A on bilateral masseteric hypertrophy evaluated with computed tomographic measurement. *Dermatol Surg.* 2003;29(5):484–89. [[PubMed](#)] [[Google Scholar](#)]
- [27] Al-Ahmad HT, Al-Qudah MA. The treatment of masseter hypertrophy with botulinum toxin type A. *Saudi Med J.* 2006;27(3):397–400. [[PubMed](#)] [[Google Scholar](#)]
- [28] Clark GT. The management of oromandibular motor disorders and facial spasms with injections of botulinum toxin. *Phys Med Rehabil Clin North Am.* 2003;14(4):727–48. [[PubMed](#)] [[Google Scholar](#)]
- [29] Mandel L, Tharakan M. Treatment of unilateral masseteric hypertrophy with botulinum toxin: Case report. *J Oral Maxillofac Surg.* 1999;57(8):1017–19. [[PubMed](#)] [[Google Scholar](#)]
- [30] Rijdsdijk BA, Van Es RJJ, Zonneveld FW, et al. Botulinum toxin type A treatment of cosmetically disturbing masseteric hypertrophy. *Ned Tijdschr Geneesk.* 1998;142(10):529–32. [[PubMed](#)] [[Google Scholar](#)]
- [31] <http://www.dentmaster.ru/articles/109>
- [32] Erdal J, Werdelin L, Prytz S, et al. Experience with long-term botulinum toxin treatment of oromandibular dystonia, guided by quantitative EMG. *Acta Neurologica Scandinavica.* 1996;94(6):210. [[Google Scholar](#)]
- [33] Cersosimo MG, Bertoti A, Roca CU, et al. Botulinum toxin in a case of hemimasticatory spasm with severe worsening during pregnancy. *Clin Neuropharmacol.* 2004;27(1):6–8. [[PubMed](#)] [[Google Scholar](#)]
- [34] Blitzer A, Brin MF, Greene PE, et al. Botulinum toxin injection for the treatment of oromandibular dystonia. *Ann Otol Rhinol Laryngol.* 1989;98(2):93–97. [[PubMed](#)] [[Google Scholar](#)]
- [35] Brin MF, Fahn S, Moskowitz C, et al. Localized injections of botulinum toxin for the treatment of focal dystonia and hemifacial spasm. *Mov Disord.* 1987;2(4):237–54. [[PubMed](#)] [[Google Scholar](#)]
- [36] Hermanowicz N, Truong DD. Treatment of oromandibular dystonia with botulinum toxin. *Laryngoscope.* 1991;101(11):1216–18. [[PubMed](#)] [[Google Scholar](#)]
- [37] Jankovic J, Orman J. Botulinum toxin for cranial-cervical dystonia: a double-blind, placebo-controlled study. *Neurology.* 1987;27:616–23. [[PubMed](#)] [[Google Scholar](#)]
- [38] Laskawi R, Rohrbach S. Oromandibular dystonia. Clinical forms, diagnosis and examples of therapy with botulinum toxin. *Laryngorhinootologie.* 2001;80(12):708–13. [[PubMed](#)] [[Google Scholar](#)]
- [39] Tan EK, Jankovic J. Botulinum toxin A in patients with oromandibular dystonia: Long-term follow-up. *Neurology.* 1999;53(9):2102–07. [[PubMed](#)] [[Google Scholar](#)]
- [40] Glaros A, Tabacchi K, Glass EG. Effect of parafunctional clenching on TMD pain and hearing loss. *J Orofacial Pain.* 1998;12(2):145–52. [[PubMed](#)] [[Google Scholar](#)]
- [41] Freund B, Schwartz M, Symington JM, et al. The use of botulinum toxin for the treatment of temporomandibular disorders: Preliminary findings. *J Oral Maxillofac Surg.* 1999;57(8):916–21. [[PubMed](#)] [[Google Scholar](#)]

- [42] Laskawi R, Drobik C, Schönebeck C. Up-to-date report of botulinum toxin type A treatment in patients with gustatory sweating (Frey's syndrome) *Laryngoscope*. 1998;108(3):381–84. [[PubMed](#)] [[Google Scholar](#)]
- [43] Lim YC, Choi EC. Treatment of an acute salivary fistula after parotid surgery: botulinum toxin type A injection as primary treatment. *Eur Arch Otorhinolaryngol*. 2008;265(2):243–45. [[PubMed](#)] [[Google Scholar](#)]
- [44] Elcio JP. BOTOX injections relieve severe facial pain. Available from: <http://www.news-medical.net/news/2005/10/25/14010.aspx>. [last cited on 2009]
- [45] Rao LB, Sangur R, Pradeep S. Application of Botulinum toxin Type A: An arsenal in dentistry. *Indian J Dent Res*. 2011;22:440–45. [[PubMed](#)] [[Google Scholar](#)]
- [46] Patel D, Mehta F, Trivedi R, Thakkar S, Suthar J. Botulinum Toxin and Gummy smile-A Review. *IOSR Journal of Dental and Medical Sciences*. 2013;4(1):1–5. [[Google Scholar](#)]
- [47] Grover S, Malik V, Kaushik A, Diwakar R, Yadav P. A Future perspective of Botox in Dentofacial Region. *J Pharm Biomed Sci*. 2014;04(05):525–31. [[Google Scholar](#)]
- [48] Clark, et al. Botulinum toxin in orofacial pain disorders. *Dent Clin N Am*. 2007;51:245–61. [[PubMed](#)] [[Google Scholar](#)]
- [49] Comella Jankovic C, Brin M. F., editors. *Dystonia: Etiology, Clinical Features, and Treatment*. Philadelphia: Lippincott Williams & Wilkins; pp. 93–112. [[Google Scholar](#)]
- [50] www.FacialAesthetics.org
- [51] <http://www.iaofe.com/about.html>.





Immun Ageing, 2013; 10: 23.

Published online 2013 Jun 13. doi: [10.1186/1742-4933-10-23](https://doi.org/10.1186/1742-4933-10-23)

PMCID: PMC3683340

PMID: [23763951](https://pubmed.ncbi.nlm.nih.gov/23763951/)

Platelet-rich plasma (PRP) in dental and oral surgery: from the wound healing to bone regeneration

Antonino Albanese,^{✉1} Maria E Licata,¹ Bianca Polizzi,¹ and Giuseppina Campisi¹

Abstract

Platelet-rich plasma (PRP) is a new approach to tissue regeneration and it is becoming a valuable adjunct to promote healing in many procedures in dental and oral surgery, especially in aging patients. PRP derives from the centrifugation of the patient's own blood and it contains growth factors that influence wound healing, thereby playing an important role in tissue repairing mechanisms. The use of PRP in surgical practice could have beneficial outcomes, reducing bleeding and enhancing soft tissue healing and bone regeneration. Studies conducted on humans have yielded promising results regarding the application of PRP to many dental and oral surgical procedures (i.e. tooth extractions, periodontal surgery, implant surgery). The use of PRP has also been proposed in the management of bisphosphonate-related osteonecrosis of the jaw (BRONJ) with the aim of enhancing wound healing and bone maturation. The aims of this narrative review are: i) to describe the different uses of PRP in dental surgery (tooth extractions and periodontal surgery) and oral surgery (soft tissues and bone tissue surgery, implant surgery and BRONJ surgery); and ii) to discuss its efficacy, efficiency and risk/benefit ratio. This review suggests that the use of PRP in the alveolar socket after tooth extractions is certainly capable of improving soft tissue healing and positively influencing bone regeneration but the latter effect seems to decrease a few days after the extraction. PRP has produced better results in periodontal therapy in association with other materials than when it is used alone. Promising results have also been obtained in implant surgery, when PRP was used in isolation as a coating material. The combination of necrotic bone curettage and PRP application seem to be encouraging for the treatment of refractory BRONJ, as it has proven successful outcomes with minimal invasivity. Since PRP is free from potential risks for patients, not difficult to obtain and use, it can be employed as a valid adjunct in many procedures in oral and dental surgery. However, further RCTs are required to support this evidence.

Keywords: PRP, Wound healing, Bone regeneration, Dental surgery, Oral surgery, Tooth extraction, Periodontal surgery, Implant surgery, BRONJ

Introduction

Research in dental and oral surgery often involves materials and procedures which are capable of improving clinical outcomes in terms of percentages of success. The goal of this research was to find a treatment approach which could reduce bleeding, promote effective bone regeneration and rapid soft-tissue healing by employing resources which are easy to use at a modest cost.

Platelet rich plasma (PRP) is a new approach to tissue regeneration: it is widely used in various surgical fields, including head and neck surgery, otolaryngology, cardiovascular surgery, and maxillofacial surgery. Commonly, PRP is used in a gel formulation, which is formed by mixing PRP (derived from the centrifugation of autologous whole blood) with thrombin and calcium chloride. PRP gel includes a high concentration of platelets and a native concentration of fibrinogen [1,2].

During wound healing, platelets are among the first cells to respond at a wound site, being critical to the initiation of this process. Besides their procoagulant effects, platelets form a rich source of important growth factors, such as platelet-derived growth factor (PDGF), transforming growth factor- β (TGF- β) 1 and 2, and vascular endothelial growth factor (VEGF); all of these are involved in the angiogenic cascade which assists in hard and soft tissue wound healing [3-5].

Recently, PRP has become a valuable adjunct to promote healing in many procedures in dental and oral surgery. They include: ablative surgical procedures, mandibular reconstruction and surgical repair of the alveolar cleft, treatment of infrabony periodontal defects and periodontal plastic surgery, as well as procedures relating to the placement of osseointegrated implants. In such procedures, the adhesive nature of PRP facilitates the easier handling of graft material, with more predictable flap adaptation and hemostasis, and a more predictable seal than is the case with primary closure alone [6-14]. Recently, the use of PRP has also been proposed in the management of bisphosphonate-related osteonecrosis of the jaw (BRONJ) or avascular necrosis, which is caused by other factors (e.g. radio-osteonecrosis), with the aim of increasing wound healing and bone maturation [15-21].

Aging patients are usually the elective patients for these procedures. From a dental point of view, these patients could be considered as *special needs patient*, requiring a specific approach; age is considered an important determinant of periodontal disease, which is the main cause of tooth loss in adulthood. Moreover, elderly patients are mostly subject to systemic diseases which influence the response to surgical treatment in terms of coagulation and tissue repair. The improvement in quality of life of aging patients in recent decades has determined a growing request for elective treatments and devices which answer their specific needs contemporaneously [22,23].

The aims of this narrative review were: i) to describe the different uses of PRP in dental surgery and oral surgery; and ii) to discuss its efficacy, efficiency and risk/benefit ratio. The different bioactive substances present in PRP and the role played in the healing process will also be elucidated.

Methods

As part of the review process, the literature was searched for published studies relating to PRP and dental surgery (e.g. alveolar wound healing and periodontal surgery) and oral surgery (i.e. soft tissues, bone tissues, and BRONJ surgery). A search of studies in the literature was conducted according to the Dickersin's search strategy [24], using MeSH terms and text words. An extensive search of bibliographical databases included: MEDLINE (1966–November week 4, 2012); EMBASE (1988–November week 4, 2012); the Cochrane Library and Best Evidence (1991–third quarter 2012); the ISI Web of Science (1965–November week 4, 2012); PubMed (1966–November week 4, 2012); Lilacs (1982–November week 4, 2012); the Cochrane Central Register of Controlled Trials (1991–third quarter 2012) and CINAHL (1982–November week 4, 2012). The following keywords were used in searching for references: *PRP, Piastrinic Gel, PRF, Oral surgery, Dental surgery, Periodontal surgery, Oral medicine, Wound Healing, ONJ, BRONJ*. Other sources were taken from the reference list of selected Papers.

All RCTs and literature reviews were considered. Case reports were used for the BRONJ session only due to the absence of original articles relating to this topic. Articles published in English from 2007 to December 2012 were considered for the discussion of PRP efficacy and efficiency. Studies based on *in vitro* trials were excluded and a total of 68 articles were finally considered. The quality of RCTs was assessed, taking into consideration the degree of bias, the presence of randomization and blindness.

This Review is structured into three main sections: the first section deals with the action mechanism of PRP on tissue wound healing; the second describes the use of PRP in dental surgery (tooth extractions and periodontal surgery) and oral surgery (soft tissues and bone tissue surgery, implant surgery and BRONJ surgery) and its advantages in terms of efficacy and efficiency. The studies selected in this section are listed in Tables 1, 2, 3 and 4 for dental surgery and oral surgery respectively. A qualitative scale with three different scores (*weak, moderate and strong*) was used in the Tables to evaluate the PRP effect. The method of scoring the PRP effect as used in the Tables, is based on the statistical significance of the efficacy of PRP, as reported in the analyzed studies: a. weak: effective but not statistically significant; b. moderate: borderline efficacy, statistically significant; c. strong: efficacy statistically significant. The third and final section discusses the risk/benefit ratio associated with the use of PRP.

Table 1

Summary of the RCTs using PRP in tooth extraction

Authors	Year of publication	Number of patients	Follow-up (wks)	Main results	Effect of PRP
Alissa et al.	2010	23	12	Statistical significant improvement in soft and bone tissue healing; statistically significant reduced post-operative pain and complications	strong
Ogundipe et al.	2011	11	12	Statistical significantly reduced pain; improvement in swelling/interincisal mouth opening and bone density but not statistically significant	moderate
Ruktowski et al.	2010	12	25	Early and significant increased radiographic density over baseline measurements in PRP-treated sites; no significant improvement in post-operative pain and bleeding after PRP application.	moderate
Celio-Mariano et al.	2012	15	1-4-8-12-24	Significant improvement in bone healing in PRP-treated sites	strong
Arenaz-Bua et al.	2012	82	12-24	No acceleration of bone formation after PRP treatment. No improvement in pain, swelling, trismus and infection.	weak
Gurbuzer et al.	2008	12	1-4	No increased osteoblastic activity in PRP treated sites	weak

Table 2

Summary of the RCTs using PRP in periodontal surgery

Authors	Year of publication	Number of patients	Treatment	Follow-up (wks)	Main results	Effect of PRP
Pradeep et al.	2009	20	Treatment of furcation defects	24	No complete closure of furcation defects	weak
Menezes et al.	2012	60	Treatment of infrabony defects	48-192	Positive effect of PRP used with other graft materials in infrabony defects but not when used alone	weak
Saini et al.	2011	20	Treatment of infrabony defects	12-24-36	Positive effect of PRP used with other graft materials in infrabony defects	moderate
Bharadwaj et al.	2011	10	Treatment of infrabony defects	24	Significant improvement in PD, CAL and bone radio-density	strong
Ozdemir et al.	2012	14	Treatment of infrabony defects	24	Positive effect of PRP used with other graft materials in infrabony defects but not when used alone	weak
Harnack et al.	2009	22	Treatment of infrabony defects	24	No improvement in PPD and CAL derived from the adjunct of PRP to other graft material	weak
Rodrigues et al.	2011		Treatment of infrabony defects	12-24-36	Better clinical results for PRP used with other graft materials in infrabony defects than with PRP used on its own	weak
Dori et al.	2008	26	Treatment of infrabony defects	48	No adjunctive benefit with the use of PRP	weak
Dori et al.	2009	30	Treatment of infrabony defects	48	No adjunctive benefit with the use of PRP	weak
Piemontese et al.	2008	60	Treatment of infrabony defects	48	No adjunctive benefit with the use of PRP	weak
Keceli et al.	2008	40	Root coverage	6-36-48	No adjunctive benefit with the use of PRP	weak

Table 3

Summary of the RCTs, using PRP in soft/bone tissue surgery and implant surgery

Authors	Year of publication	Number of patients	Treatment	Follow-up (wks)	Main results	Effect of PRP
Anitua et al.	2006	295	Implantology	8	Improvement in implant prognosis	strong
Anand et al.	2012	11	Implantology	12-24-36-48	Improved early bone apposition around the implant	strong
Gentile et al.	2010	15	Reconstructive surgery of the jaw	2-4-12-24	Efficacy of PRP treatment in terms of patient satisfaction and low-morbidity	strong
Wojtowicz et al.	2007	16	Augmentation of mandibular bone	12	PRP is more effective than bone marrow, containing CD34+ cells	strong
Daif	2012	24	Bone regeneration of mandibular fractures	1-12-24	Direct application of the PRP along the fracture lines may enhance bone regeneration in mandibular fractures	strong
Khairy et al.	2012	15	Sinus lift	12-24	PRP- enriched bone grafts were associated with superior bone density at 6 months post grafting	strong
Poeschl et al.	2012	14	Sinus lift	28	Increased new bone formation when PRP was used	strong
Cabbar et al.	2011	10	Sinus lift	28	No statistically significant differences were observed	weak

Table 4

Summary of the case reports using PRP in the BRONJ surgery

Authors	Year of publication	Number of patients	Type of lesion	Treatment options	Follow-up (Mths)	Main results	Effect of PRP
Curi et al.	2007	3	Jaw lesions		6-8	Resolution of all lesions	strong
Lee et al.	2007	2	Complications of dental implants: oral sinus communication and lesion on the jaw ramus	Closure of the oroantral communication by rotating a large palatally-based pedicle flap over the defect; surgical debridement of the lesion of the ramus	6-9	Resolution of pain and complete closure of exposed bone	strong
Adornato et al.	2007	12	Soft tissue ulcerations and bone exposure	Marginal resection limited to the alveolar bone	6	Ten patients showed complete soft tissue healing	strong
Cetiner et al.	2009	1	Exposed necrotic bone in the alveolus	Marginal resection of the mandibular necrotic bone	6	Complete healing of the oral mucosa and alveolar bone at the surgical site	strong
Bocanegra et al.	2012	8	Exposed necrotic bone in the mandibula and maxilla	Removal of necrotic bone and curettage of the underlying bone	14	Fast mucosal healing, reduced need for analgesics and resolution of mouth lesions, without evidence of exposed bone.	strong
Mozzati et al.	2012	32	Jaw lesions	Resection of the necrotic bone		The orthopantomogram X-ray and computed tomography performed before and after surgery showed successful outcomes	strong
Coviello et al.	2012	7	Jaw lesions	Surgical debridement and sequestrectomy	3	Improvement in wound healing and reduction of bone exposure	strong

The PRP action mechanism

Platelet-rich plasma (PRP) is defined as a high concentration of autologous platelets in a small volume of autologous plasma [25,26]. Specifically, PRP is a platelet concentration with at least 1,000,000/1 L in a 5 mL volume of plasma, when normal human platelet counts in the blood range from 150,000/1 L to 350,000/1 L. The platelets contained in this concentrate of autologous plasma release their alpha granules after the coagulation process has been locally triggered in the wound site. These alpha granules contain a cocktail of growth factors which promote proliferation, chemotaxis and the differentiation of cells, which are essential to osteogenesis. Thus, besides its procoagulant effect, PRP is a source of growth factors involved in initiating and sustaining wound healing by accelerating bone repair, promoting fibroblast proliferation, and increasing tissue vascularity [27].

Platelet-rich plasma gel is formed by mixing PRP (derived from the centrifugation of autologous whole blood) with thrombin and calcium chloride. Adding thrombin and calcium chloride to PRP automatically activates the alpha granules to release the following biological growth factors: platelet-derived growth factor (PDGF), transforming growth factor-beta (TGF- β), vascular endothelial growth factor (VEGF), insulin-like growth factor I, epidermal growth factor (EGF) and epithelial cell growth factor [3].

The major effects of PRP are derived from PDGF, which has been identified as an important protein for hard- and soft-tissue healing. PDGF has been shown to stimulate chemotaxis, mitogenesis and the replication of stem cells at the site of a wound to the site of tissue injury. This results in the formation of matrix bone and angiogenesis by stimulating increased levels of VEGF. This in turn may lead to accelerate soft-tissue healing due to neo-vascularization. PDGF also stimulates the production of fibronectin, a cell adhesion molecule used in cellular proliferation and migration during healing, including osteoconduction and hyaluronic acid, and it assists in promoting wound contraction and remodelling [28].

Other cytokines released by PRP alpha granules are TGF- β 1 and TGF- β 2, both of which are involved in connective tissue repair and bone regeneration. Their most important role appears to be to stimulate fibroblast chemotaxis and the production of collagen and fibronectin by cells while inhibiting collagen degradation by decreasing proteases and increasing protease inhibitors. *In vitro* and *in vivo* studies have also shown that TGF increases the proliferation of mesenchymal stem cells and osteoblasts, leading to bone regeneration. Specifically, TGF- β 2 has been shown to increase osteoblast and osteoclast activity. An increase in TGF- β 2 may accelerate bone regeneration by controlling the activity of osteoblasts and osteoclasts [29,30].

The use of PRP in dental surgery

The effects of PRP on healing the alveolar socket after tooth extraction

Tooth extraction is a common dental procedure which involves severely decayed, periodontally affected, non-restorable or impacted teeth. These procedures can be associated with significant postoperative pain, particularly when third impacted molars are extracted. Furthermore, prolonged bleeding can be experienced by patients especially by those undergoing anticoagulant therapy [31]. To address post-operative discomfort and to enhance tissue repair mechanisms, many procedures (i.e. fibrin sponge, biostimulation with LASER) have been performed which promote the healing process [32,33].

Recently, the use of PRP has been proposed as a way of obtaining high concentrations of growth factors involved in tissue healing and regeneration. The therapeutic strategy of this approach is to promote the process of tissue repair, improving the quality of healing and healing time [8]. However, very few studies have been carried out on humans and contradictory results have been produced regarding the efficacy of PRP. Promising results were reported by Alissa *et al.* (2010), who conducted a pilot study on the effect of PRP on the healing of the hard and soft tissues of extraction sockets. Soft tissue healing was significantly improved in patients treated with PRP compared with patients of the control group (no treatment). Moreover, patients untreated with PRP experienced complications (dry sockets and acutely inflamed alveolus), which were considered to be borderline statistically significant. Radiographic evaluation revealed a statistically significant difference only for sockets with a dense homogeneous trabecular pattern. Of interest, Alissa *et al.* (2010) also analyzed the post-operative pain of patients of the two groups (treated and untreated) and they reported significantly more pain in the control group, especially in the first three days post intervention [34].

A significant response to pain in patients undergoing a surgical extraction of a single impacted third molar and using PRP was also reported by Ogunipe *et al.* (2011). Moreover, an improvement in swelling and the interincisal mouth opening was obtained in these patients: the scores for lamina dura, trabecular pattern, and bone density were much improved among patients in the PRP group, even if this difference was not statistically significant [35].

Similar findings have been reported by Ruktowski *et al.* (2010) who used digital radiography and Computer Tomography (CT) scan analysis to track changes in radiographic density at PRP-treated sites in comparison to ipsilateral not-PRP treated sites. The PRP-treated sites demonstrated early and a significant increased radiographic density over baseline measurements following tooth removal. The greatest benefit attributed to PRP is during the initial 2-week post-operative healing time period: 6 weeks for control extraction sites to reach comparable bone density were required whereas PRP-treated sites achieved this at week 1. Post-operative pain and bleeding were not significantly affected by PRP application. [36]. Likewise, a more recent study by Celio-Mariano *et al.* (2012) showed a greater radiographic bone density in the PRP group, thereby demonstrating a significant improvement in bone healing in the sockets after extraction of mandibular third molars as compared to the control group [37].

In a prospective split-mouth study conducted by Arenaz-Bua *et al.* (2010) the efficacy of PRP in promoting bone regeneration after third molar extraction was analyzed. The Authors observed no further acceleration in bone formation at 6 months nor did they observe statistically significant differences between the groups regarding pain, swelling, trismus and infection throughout the post-operative period. [38]. Similarly, in a study by Gurbuzer *et al.* (2008) (using scintigraphy), the application of PRP on its own to soft tissue impacted mandibular third molar extraction sockets failed to increase the osteoblastic activity in post-surgical weeks 1 and 4 in comparison to non-PRP-treated sockets [39].

The above review of the literature suggests that the use of PRP in the alveolar socket after tooth extractions is certainly capable of improve soft tissue healing but there is insufficient evidence which supports the efficacy of PRP in improving bone regeneration. Similarly, the efficiency of PRP is controversial since the use of PRP in tooth extraction sites seems to influence the early phase of bone healing, thereby facilitating and accelerating bone formation in the initial period after tooth extraction, its influence decreasing after a few days. Not univocal results were also obtained for post-operative pain but conclusive considerations in terms of efficacy and efficiency could not be formulated. The aforementioned studies are listed in Table 1.

The use of PRP in periodontal surgery

The growth factors present in PRP are capable of forming a fibrin clot, promoting fibroblast proliferation and up-regulating collagen synthesis in the extracellular matrix. Thus, the use of PRP at injury sites might be able to promote wound healing and the regeneration of periodontal soft tissues [36]. Moreover, the ability of these factors to accelerate bone repair by increasing the mitosis of osteoblasts and tissue vascularity might be useful in the treatment of infra-bony defects [40,41]. However, the therapeutic efficacy of PRP in periodontal therapy still remains controversial.

The results of a recent systematic review regarding the efficacy of PRP in periodontal therapy have revealed that it is capable of improving gingival recession but not clinical attachment level in chronic periodontitis [42]. Moreover, Pradeep *et al.* (2009), who conducted a study on the treatment of mandibular furcation defects, have reported the lack of complete closure of furcation defects despite a significant improvement; this implies a limited role for autologous PRP as a regenerative material [43]. However, the efficacy of PRP on its own is difficult to evaluate since the majority of studies have been conducted by testing PRP in combination with graft materials in order to enhance the outcome of regenerative surgery. Moreover, a barrier membrane was used to cover the defects in most clinical studies and, thus, the effects of PRP may have been masked by the effects of the barrier.

The results of the systematic review by Del Fabbro *et al.* (2011) revealed that PRP may exert a positive adjunctive effect when used in combination with graft materials for the treatment of intrabony defects. However, no significant benefit of PRP was found for the treatment of gingival recession [44]. Similarly, two controlled clinical trials investigating the efficacy of PRP combined with other graft materials in the treatment of intraosseous periodontal defects reported a significantly more favorable clinical improvement in periodontal sites treated with the combination of PRP and the graft material than in those treated with the graft material alone [45,46]. Contemporaneously, Bharadwaj *et al.* (2011) found that the adjunct of PRP to bone graft appeared to be beneficial in the treatment of human periodontal intrabony defects. [47].

Different results have been reported by other Authors, who showed no significant benefits regarding the additional use of PRP to graft materials in the treatment of infra-bony defects. Ozdemir *et al.* (2012) showed that PRP combined with a graft material was effective in the treatment of intrabony defects after a 6-month healing period but no additional statistically significant improvements were observed when PRP was used [48]. Similar results

were reached by Harnack *et al.* (2009) using the same combination of materials [49]. Rodrigues *et al.* (2011) concluded that both PRP and PRP combined with bovine anorganic bone mineral (ABM) resulted in a significant clinical improvement for the treatment of human periodontal intrabony defects but there was a preponderance of improved clinical results with the addition of ABM to PRP [50]. No additional effects were found by Döri *et al.* (2008, 2009) and Piemontese *et al.* (2008). Throughout all their studies, they concluded that the use of PRP failed to enhance the results obtained with the use of the graft material used on its own [51-53].

Few clinical comparative studies have investigated the use of PRP in the treatment of gingival recession. Keceli *et al.* (2008) did not reveal promising results and nor did they observe differences in clinical outcomes between connective tissue grafts (CTG) and a CTG-PRP combination [54]. The results of this analysis reflect the limited and heterogeneous data available and suggest that the specific selection of agents/procedures combined with PRP could be important. The aforementioned studies are listed in the Table 2.

The employ of PRP in oral surgery

The use of PRP in soft tissues and bone tissues surgery and implant surgery

Animal and human studies have demonstrated that PRP enhances and accelerates soft tissue repair and bone regeneration [3,55]. In the field of bone tissue surgery, a recent study by Daif (2012) investigated the effect of autologous PRP on bone regeneration in mandibular fractures. He concluded that direct application of the PRP along the fracture lines may enhance bone regeneration [56]. Wojtowicz *et al.* (2007) compared the effects of stimulating the osteogenesis of the alveolar bone by transplants of autologous bone marrow and freshly-isolated mononuclear cells from bone marrow, containing CD34+ cells and PRP. It was shown that newly-formed bone increased under the influence of PRP. This treatment was more effective than that using the population of CD-34 bone marrow-derived stem cells [57].

A Cochrane review of Esposito *et al.* (2010) concluded that PRP treatment did not seem to improve the clinical outcome of sinus lift procedures with autogenous bone or bone substitutes [58]. In addition, a study by Khairy *et al.* (2012) evaluated the bone quality in sinus which had been augmented with autogenous bone with or without PRP. The conclusion was that enrichment with PRP did not significantly improve bone density at 3 months post grafting but PRP-enriched bone grafts were associated with superior bone density at 6 months post grafting [59]. Poeschl (2012) obtained successful results when PRP was used in combination with a graft material in maxillary sinus augmentation [60]. Cabbar (2011) *et al.* compared a bovine bone xenograft with PRP and without PRP to augment the human maxillary sinus in preparation for receiving dental implants. The conclusion of this study stated was that the combination of the xenograft and PRP did not have any effect on new bone formation and implant stabilization [61].

The preparation of PRP, as applied to an implant surface, adheres to metal and might create a new dynamic surface which could potentially show biological activity. In 2006, Anitua showed that the osseointegration of implants was enhanced by coating the implant surface with PRP prior to insertion into the alveolus [62]. Similarly, Gentile *et al.* (2010) reported their experience on 15 cases, including reconstructive surgery of the jaw, post-extraction alveolar bone regeneration, and oral implantology. The results of their study revealed the efficacy of the PRP treatment in terms of post-operative patients' satisfaction and low-morbidity [63]. Anand *et al.* (2012) have recently proposed that the use of a novel technique (of coating the implant with PRP) could improve the prognosis of the treatment regarding an immediate loading protocol [64].

The results of these studies demonstrate that PRP is effective in soft tissue healing and bone regeneration. The combination of PRP application with other biomaterials seems to be promising as regards sinus lifting, but the results depend on the material used. Promising results have also been obtained in implant surgery, using PRP on its own as a coating material. The aforementioned studies are listed in Table 3.

The use of PRP in BRONJ surgery

Some researchers have proposed the use of PRP in BRONJ surgery [15-21]. BRONJ is currently recognized as a significant complication, which is related to the use of bisphosphonates (BPs), a widely-used class of drugs employed in the preventative treatment of various pathologies joined by the same alteration of bone turn-over (i.e. osteoporosis, bone metastasis, associated with solid tumours and multiple myeloma, malignant hypercalcemia). BPs are capable of inhibiting osteoclast-mediated bone resorption, also displaying anti-angiogenetic activity. The bones of patients treated with BPs are, therefore, poorly vascularized and poorly supplied with the substances necessary for wound healing [65,66].

The use of these drugs could delay the onset of BRONJ, which is defined as an avascular area of necrotic bone in the maxillofacial area, with or without exposed bone. This area of osteonecrosis always appears in the traumatized bone. Although some of the cases reported were asymptomatic, most of them resulted in complications, such as an altered sensation in the affected area (e.g. mandibular alveolar nerve), purulent exudates, oral-cutaneous fistula, and mandibular fractures [65]. BRONJ management is currently controversial, ranging from medical to surgical treatment, with no definitive standard of care. Indeed, the response to radical surgery is less predictable than in other situations involving bone necrosis, such as radiotherapy or osteomyelitis [67]. Aggressive surgical debridement is also controversial due to the risk of worsening bone exposure. Occasionally, the bone is left exposed due to the difficulty of treating the lesion [68].

PRP therapy has been proposed as a complement to conservative surgery in order to enhance bone healing. The rationale for the employment of PRP in patients affected by BRONJ is based on the thesis that the presence of growth factors (usually repressed by BPs) constitutes a substitute stimulation to bone healing, which is similar to physiological healing. The growth factors in PRP might accelerate epithelial wound healing, decrease tissue inflammation after surgery, improve the regeneration of bone and soft tissues, and promote tissue vascularization. The additional advantages related to the use of this product are its biocompatibility and safety, as an autologous product [1,3].

Few case series studies relating to use of PRP in treating BRONJ have been published: Cetiner *et al.*, 2009 described a case of zoledronate-associated BRONJ after tooth exodontia in a 68-year-old man with multiple myeloma, which was treated with surgical debridement plus PRP with a positive outcome after a 6-month follow-up period [15]. Curi *et al.*, 2007 reported using this treatment in three cases of jaw lesions, which were followed up for 6 months in two cases and 8 months in one [16]. Lee *et al.*, 2007 reported two cases which were successfully treated, which were secondary to complications of dental implants: one involved left oral sinus communication (with a 9-month follow-up period) and the other case involved a lesion on the left jaw ramus (6-month follow-up) [17].

In the study conducted by Bocanegra *et al.* (2012) eight patients were selected and all improved over a mean period of 3 weeks (2–4 weeks) after treatment with: fast mucosal healing, a reduced need for analgesics and a resolution of mouth lesions. These patients continued with follow-up visits, without any evidence of exposed bone after 14 months [18]. Adornato *et al.* (2007) treated twelve patients who presented with soft tissue ulcerations and bone exposure with measurements ranging from 5 to 25 mm. These lesions had not responded to six months of treatment with cleaning therapies, 0.12% chlorhexidine rinses and intermittent antibiotic therapies. These patients were treated with conservative marginal resections of the alveolar bone with primary closure over the bony defect, PRP and a resorbable membrane under antibiotic coverage. After six months, ten patients showed complete soft tissue healing with one patient displaying a recurrence of epithelial dehiscence; another patient, with recovery by secondary intention, did not show any regression of bone exposure [19].

Positive results were also obtained by Mozzati *et al.* (2012), who conducted a study on 32 patients treated with intravenous BPs for oncological pathologies affected by BRONJ. The patients were treated by a resection of the necrotic bone with primary closure of the mucosa over the bony defect using PRP. The orthopantomogram and computed tomography performed before and after surgery revealed successful outcomes [20]. Similarly Coviello *et al.* (2012), who reported the cases of 7 patients with multiple myeloma treated with BPs, concluded that the use of PRP enhances wound healing and reduce bone exposure and would be an effective treatment protocol to use in BRONJ subjects [21]. The results of these studies showed that the combination of necrotic bone curettage and PRP application seem to be promising for the treatment of refractory BRONJ. Since an efficient standard treatment has not yet been established, this combined approach can be considered a treatment option as it has demonstrated successful outcomes and minimal invasivity.

The risk/benefit ratio and the use of PRP

PRP is an autologous preparation, utilizing the patient's own blood in a significantly small quantity. For this reason, it is safe and there have been no published references relating to the risk of infections, disease transmission (such as HIV, hepatitis, or Creutzfeldt-Jacob disease), immunogenic reactions or any other adverse effects which exist with allografts or xenografts [69].

In the past, the use of bovine thrombin (an activator which allows polymerization of fibrin into an insoluble gel), used in the preparation of PRP, was associated with the risk of life-threatening coagulopathies [42]. However, the adverse reactions reported were related to the source and quantity of thrombin used. The use of bovine thrombin in PRP in low doses (<200 units), topically with no entry into systemic circulation and already clotted when coming into contact with human tissues, would not be dangerous as an immunologic reaction. [3]. Moreover, in the second generation platelet concentrate, PRP activation was effected using only calcium chloride, thus eliminating the risk associated with thrombin. No adverse effects linking the use of calcium chloride have been reported in the literature [70,71].

Although no undesirable effects have been reported in the many clinical cases subjected to PRP therapy, hypotheses as to the over-expression of growth factors and their receptors related to tumour and dysplastic tissues have been postulated. These hypotheses are founded on the fact that growth factors appear to regulate different cellular processes, such as mitogenesis, chemotaxis, cell differentiation and metabolism. However, the phenomenon leading to neoplastic growth requires more continuous doses of growth factors over time than those applied in PRP therapy and sufficient delivery, taking into account that extracellular growth factors degrade within 7–10 days. Moreover, there are previously existing alterations for developing a neoplasm and, in any case, the use of PRP should be avoided: in patients with precancerous oral conditions and in the vicinity of precancerous lesions (oral leukoplakia, erythroplasia or solar cheilitis); areas of oral epithelial dysplasia; and in patients with a prior history of exposure to carcinogens or primary oral squamous cell carcinoma [72].

The only disadvantage of PRP preparations would be the cost versus the outcome benefit. The doubtful success of PRP may not justify the cost to the clinician of buying the PRP-processing system and the disposable kits or the cost to the patient for paying for this treatment. Furthermore, an additional but less important inconvenience for the treatment would be that patients have to be subjected to a venipuncture and blood drawing procedure in preparation for PRP [13]. On the other hand, PRP has the advantage to being easily obtainable and not time-consuming for the patient and/or clinician. Even if preparation of PRP involves an additional step to the surgical procedure, it takes approximately 30 minutes and is best performed by a surgical assistant under the supervision of a trained dental surgeon. This can be done simultaneously while performing the surgery, and it, therefore, does not significantly increase the chair time of the operator and the patient [3,47].

Conclusion

PRP preparations have been proposed for several uses in dental and oral surgery. The ease with which these preparations are used might be helpful to the dental professional in many surgical procedures, and their safety might encourage their wide employment [1,3,47,69]. The scientific evidence regarding the efficacy and efficiency of PRP is still controversial, given the paucity of RCTs relating to this topic and, of these, the majority has been conducted using different graft materials and applying different procedures.

This Review of the literature suggests that the use of PRP in the alveolar socket after tooth extractions is certainly able to improve soft tissue healing and positively influence bone regeneration but this latter effect seems to decrease a few days after extraction. PRP has revealed better results in periodontal therapy in association with other materials than when it is used alone, suggesting that the specific selection of agents/procedures combined with PRP could be important [34-39].

Promising results have also been obtained in implant surgery, using PRP on its own as a coating material. Furthermore, the combination of PRP application with other biomaterials seems to be favorable as regards sinus lifting even if the choice of material used is critical in this field [58-64]. The combination of necrotic bone curettage and PRP application seem to be encouraging for the treatment of refractory BRONJ, as it has demonstrated successful outcomes with minimal invasivity [15-21]. Since it is free from potential risks to patients, not difficult to obtain and use, PRP can be employed as a valid adjunct to many procedures in oral and dental surgery. However, further RCTs are required to support the use of PRP in current practice.

Competing interests

The authors declare the absence of any competing financial interest in the writing of this review.

References

- Carlson NE, Roach RB. Platelet-rich plasma: clinical applications in dentistry. *J Am Dent Assoc.* 2002;**133**:1383–1386. [PubMed] [Google Scholar]
- Kao RT, Murakami S, Beirne OR. The use of biologic mediators and tissue engineering in dentistry. *Periodontol 2000.* 2009;**50**:127–153. doi: 10.1111/j.1600-0757.2008.00287.x. [PubMed] [CrossRef] [Google Scholar]
- Nikolidakis D, Jansen JA. The biology of platelet-rich plasma and its application in oral surgery: literature review. *Tissue Engineering: Part B.* 2008;**14**:249–258. doi: 10.1089/ten.teb.2008.0062. [PubMed] [CrossRef] [Google Scholar]
- El-Sharkawy H, Kantarci A, Deady J, Hasturk H, Liu H, Alshahat M, Van Dyke TE. Platelet rich plasma: growth factors and pro- and anti-inflammatory properties. *J Periodontol.* 2007;**78**:661–669. doi: 10.1902/jop.2007.060302. [PubMed] [CrossRef] [Google Scholar]
- Anitua E, Andia I, Ardanza B, Nurden P, Nurden AT. Autologous platelets as source of proteins for healing and tissue regeneration. *Thromb Haemost.* 2004;**91**:4–15. [PubMed] [Google Scholar]
- Marx RE, Carlson ER, Eichstaedt RM, Schimmele SR, Strauss JE, Georgeff KR. Platelet rich plasma. *Oral Surg Oral Med Oral Pathol.* 1998;**85**:638–646. doi: 10.1016/S1079-2104(98)90029-4. [PubMed] [CrossRef] [Google Scholar]
- Fennis JP, Stoelting PJ, Jansen JA. Mandibular reconstruction: a histological and histomorphometric study on the use of autogenous scaffolds, particulate corticocancellous bone grafts and platelet rich plasma in goats. *Int J Oral Maxillofac Surg.* 2004;**33**:48–55. doi: 10.1054/ijom.2003.0452. [PubMed] [CrossRef] [Google Scholar]
- Del Corso M, Vervelle A, Simonpieri A, Jimbo R, Inchigolo F, Sammartino G, Dohan Ehrenfest DM. Current knowledge and perspectives for the use of platelet-rich plasma (PRP) and platelet-rich fibrin (PRF) in oral and maxillofacial surgery part 1: Periodontal and dentoalveolar surgery. *Curr Pharm Biotechnol.* 2012;**13**:207–230. [PubMed] [Google Scholar]
- Plachokova AS, Nikolidakis D, Mulder J, Jansen JA, Creugers NH. Effect of platelet-rich plasma on bone regeneration in dentistry: a systematic review. *Clin Oral Implants Res.* 2008;**19**:539–545. doi: 10.1111/j.1600-0501.2008.01525.x. [PubMed] [CrossRef] [Google Scholar]
- Bae JH, Kim YK, Myung SK. Effects of platelet-rich plasma on sinus bone graft: meta-analysis. *J Periodontol.* 2011;**82**:660–667. doi: 10.1902/jop.2010.100529. [PubMed] [CrossRef] [Google Scholar]
- Holly D, Mracna J. The use of platelet rich plasma with guided tissue regeneration in defects caused by periodontal diseases. *Bratisl Lek Listy.* 2009;**110**:669–671. [PubMed] [Google Scholar]
- Choi BH, Im CJ, Huh JY, Suh JJ, Lee SH. Effect of platelet-rich plasma on bone regeneration in autogenous bone graft. *Int J Oral Maxillofac Surg.* 2004;**33**:56–59. doi: 10.1054/ijom.2003.0466. [PubMed] [CrossRef] [Google Scholar]
- Arora NS, Ramanayake T, Ren YF, Romanos GE. Platelet-rich plasma in sinus augmentation procedures: a systematic literature review: Part II. *Implant Dent.* 2010;**19**:145–157. doi: 10.1097/ID.0b013e3181cd706d. [PubMed] [CrossRef] [Google Scholar]
- Nikolidakis D, Wolke JG, Jansen JA. Effect of platelet-rich plasma on the early bone formation around Ca-P-coated and non-coated oral implants in cortical bone. *Clin Oral Implants Res.* 2008;**19**:207–213. doi: 10.1111/j.1600-0501.2007.01456.x. [PubMed] [CrossRef] [Google Scholar]
- Cetiner S, Sucak GT, Kahraman SA, Aki SZ, Kocakahaoglu B, Gultekin SE, Cetiner M, Haznedar R. Osteonecrosis of the jaw in patients with multiple myeloma treated with zoledronic acid. *J Bone Miner Metab.* 2009;**27**:435–443. doi: 10.1007/s00774-009-0047-9. [PubMed] [CrossRef] [Google Scholar]
- Curi MM, Cossolin GS, Koga DH, Araújo SR, Feher O, dos Santos MO, Zardetto C. Treatment of avascular osteonecrosis of the jaw in cancer patients with a history of bisphosphonate therapy by combining bone resection and autologous platelet-rich plasma: report of 3 cases. *J Oral Maxillofac Surg.* 2007;**65**:349–355. doi: 10.1016/j.joms.2005.12.051. [PubMed] [CrossRef] [Google Scholar]
- Lee CY, David T, Nishime M. Use of platelet-rich plasma in the management of oral bisphosphonate-associated osteonecrosis of the jaw: a report of 2 cases. *J Oral Implantol.* 2007;**33**:371–382. doi: 10.1563/1548-1336(2007)33[371:UOPPIT]2.0.CO;2. [PubMed] [CrossRef] [Google Scholar]
- Bocanegra-Perez S, Vicente-Barrero M, Knezevic M, Castellano-Navarro JM, Rodriguez-Bocanegra E, Rodriguez-Millares J, Perez-Plasencia D, Ramos-Macias A. Use of platelet-rich plasma in the treatment of bisphosphonate-related osteonecrosis of the jaw. *Int J Oral Maxillofac Surg.* 2012;**41**:1410–1415. doi: 10.1016/j.ijom.2012.04.020. [PubMed] [CrossRef] [Google Scholar]

19. Adornato MC, Morcos I, Rozanski J. The treatment of bisphosphonate-associated osteonecrosis of the jaws with bone resection and autologous platelet-derived growth factors. *J Am Dent Assoc.* 2007;**138**:971–977. [[PubMed](#)] [[Google Scholar](#)]
20. Mozzati M, Gallesio G, Arata V, Pol R, Scoletta M. Platelet-rich therapies in the treatment of intravenous bisphosphonate-related osteonecrosis of the jaw: a report of 32 cases. *Oral Oncol.* in press. [[PubMed](#)]
21. Coviello V, Peluso F, Dehkhargani SZ, Verdugo F, Raffaelli L, Manicone PF, D'Addona A. Platelet-rich plasma improves wound healing in multiple myeloma bisphosphonate-associated osteonecrosis of the jaw patients. *J Biol Regul Homeost Agents.* 2012;**26**:151–155. [[PubMed](#)] [[Google Scholar](#)]
22. Huttner EA, Machado DC, de Oliveira RB, Antunes AG, Hebling E. Effects of human aging on periodontal tissues. *Spec Care Dentist.* 2009;**29**:149–155. doi: 10.1111/j.1754-4505.2009.00082.x. [[PubMed](#)] [[CrossRef](#)] [[Google Scholar](#)]
23. McCreary C, Ni Riordáin R. Systemic diseases and the elderly. *Dent Update.* 2010;**37**:604–607. [[PubMed](#)] [[Google Scholar](#)]
24. Dickersin K, Scherer R, Lefebvre C. Identifying relevant studies for systematic reviews. *BMJ.* 1994;**309**:1286–91. doi: 10.1136/bmj.309.6964.1286. [[PMC free article](#)] [[PubMed](#)] [[CrossRef](#)] [[Google Scholar](#)]
25. Marx RE. Platelet-rich plasma: evidence to support its use. *J Oral Maxillofac Surg.* 2004;**62**:489–496. doi: 10.1016/j.joms.2003.12.003. [[PubMed](#)] [[CrossRef](#)] [[Google Scholar](#)]
26. Marx RE. Platelet-rich plasma (PRP): what is PRP and what is not PRP? *Implant Dent.* 2001;**10**:225–228. doi: 10.1097/00008505-200110000-00002. [[PubMed](#)] [[CrossRef](#)] [[Google Scholar](#)]
27. Marx RE. In: *Tissue Engineering: Applications in Maxillofacial Surgery and Periodontics.* Lynch SE, Genco RJ, Marx RE, editor. Chicago: Quintessence; 1999. Platelet-rich plasma: a source of multiple autologous growth factors for bone grafts; pp. 71–82. [[Google Scholar](#)]
28. Yang D, Cheng J, Jing Z, Jin D. Platelet-derived growth factor (PDGF)-AA: a self-imposed cytokine in the proliferation of human fetal osteoblasts. *Cytokine.* 2000;**12**:1271–1274. doi: 10.1006/cyto.2000.0707. [[PubMed](#)] [[CrossRef](#)] [[Google Scholar](#)]
29. Cochran DL, Wozney JM. Biological mediators for periodontal regeneration. *Periodontology.* 2000;**19**:40–58. [[PubMed](#)] [[Google Scholar](#)]
30. Rose LF, Rosenberg E. Bone grafts and growth and differentiation factors for regenerative therapy: a review. *Pract Proced Aesthet Dent.* 2001;**13**:725–734. [[PubMed](#)] [[Google Scholar](#)]
31. Bouloux GF, Steed MB, Perciaccante VJ. Complications of third molar surgery. *Oral Maxillofac Surg Clin North Am.* 2007;**19**:117–128. doi: 10.1016/j.coms.2006.11.013. [[PubMed](#)] [[CrossRef](#)] [[Google Scholar](#)]
32. Bacci C, Maglione M, Favero L, Perini A, Di Lenarda R, Berengo M, Zanon E. Management of dental extraction in patients undergoing anticoagulant treatment. Results from a large, multicentre, prospective, case-control study. *Thromb Haemost.* 2010;**104**:972–975. doi: 10.1160/TH10-02-0139. [[PubMed](#)] [[CrossRef](#)] [[Google Scholar](#)]
33. Lins RD, Dantas EM, Lucena KC, Catão MH, Granville-Garcia AF, Carvalho Neto LG. Biostimulation effects of low-power laser in the repair process. *An Bras Dermatol.* 2010;**85**:849–855. doi: 10.1590/S0365-05962010000600011. [[PubMed](#)] [[CrossRef](#)] [[Google Scholar](#)]
34. Alissa R, Esposito M, Horner K, Oliver R. The influence of platelet-rich plasma on the healing of extraction sockets: an explorative randomised clinical trial. *Eur J Oral Implantol.* 2010;**3**:121–134. [[PubMed](#)] [[Google Scholar](#)]
35. Ogundipe OK, Ugboko VI, Owotade FJ. Can autologous platelet-rich plasma gel enhance healing after surgical extraction of mandibular third molars? *J Oral Maxillofac Surg.* 2011;**69**:2305–2310. doi: 10.1016/j.joms.2011.02.014. [[PubMed](#)] [[CrossRef](#)] [[Google Scholar](#)]
36. Rutkowski JL, Johnson DA, Radio NM, Fennell JW. Platelet rich plasma to facilitate wound healing following tooth extraction. *J Oral Implantol.* 2010;**36**:11–23. doi: 10.1563/AAID-JOI-09-00063. [[PubMed](#)] [[CrossRef](#)] [[Google Scholar](#)]
37. Célio-Mariano R, Morais de Melo W, Carneiro-Avelino C. Comparative radiographic evaluation of alveolar bone healing associated with autologous platelet-rich plasma after impacted mandibular third molar surgery. *J Oral Maxillofac Surg.* 2012;**70**:19–24. doi: 10.1016/j.joms.2011.03.028. [[PubMed](#)] [[CrossRef](#)] [[Google Scholar](#)]
38. Arenaz-Búa J, Luaces-Rey R, Sironvalle-Soliva S, Otero-Rico A, Charro-Huerta E, Patiño-Seijas B, García-Rozado A, Ferreras-Granados J, Vázquez-Mahía I, Lorenzo-Franco F, Martín-Sastre R, López-Cedrún JL. A comparative study of platelet-rich plasma, hydroxyapatite, demineralized bone matrix and autologous bone to promote bone regeneration after mandibular impacted third molar extraction. *Med Oral Patol Oral Cir Bucal.* 2010;**15**:483–489. [[PubMed](#)] [[Google Scholar](#)]
39. Gürbüzler B, Pıkdöken L, Urhan M, Süer BT, Narin Y. Scintigraphic evaluation of early osteoblastic activity in extraction sockets treated with platelet-rich plasma. *J Oral Maxillofac Surg.* 2008;**66**:2454–2460. doi: 10.1016/j.joms.2008.03.006. [[PubMed](#)] [[CrossRef](#)] [[Google Scholar](#)]
40. Kawase T, Okuda K, Wolff LF, Yoshie H. Platelet-rich plasma-derived fibrin clot formation stimulates collagen synthesis in periodontal ligament and osteoblastic cells in vitro. *J Periodontol.* 2003;**74**:858–864. doi: 10.1902/jop.2003.74.6.858. [[PubMed](#)] [[CrossRef](#)] [[Google Scholar](#)]
41. Kanno T, Takahashi T, Tsujisawa T, Ariyoshi W, Nishihara T. Platelet-rich plasma enhances human osteoblast-like cell proliferation and differentiation. *J Oral Maxillofac Surg.* 2005;**63**:362–369. doi: 10.1016/j.joms.2004.07.016. [[PubMed](#)] [[CrossRef](#)] [[Google Scholar](#)]
42. Martínez-Zapata M, Martí-Carvajal A, Solà I, Bolibar I, Angel Expósito J, Rodríguez L, García J. Efficacy and safety of the use of autologous plasma rich in platelets for tissue regeneration: a systematic review. *Transfusion.* 2009;**49**:44–56. doi: 10.1111/j.1537-2995.2008.01945.x. [[PubMed](#)] [[CrossRef](#)] [[Google Scholar](#)]
43. Pradeep AR, Pai S, Garg G, Devi P, Shetty SK. A randomized clinical trial of autologous platelet-rich plasma in the treatment of mandibular degree II furcation defects. *J Clin Periodontol.* 2009;**36**:581–588. doi: 10.1111/j.1600-051X.2009.01428.x. [[PubMed](#)] [[CrossRef](#)] [[Google Scholar](#)]
44. Del Fabbro M, Bortolin M, Taschieri S, Weinstein R. Is platelet concentrate advantageous for the surgical treatment of periodontal diseases? A systematic review and meta-analysis. *J Periodontol.* 2011;**82**:1100–1111. doi: 10.1902/jop.2010.100605. [[PubMed](#)] [[CrossRef](#)] [[Google Scholar](#)]
45. Menezes LM, Rao J. Long-term clinical evaluation of platelet-rich plasma in the treatment of human periodontal intraosseous defects: a comparative clinical trial. *Quintessence Int.* 2012;**43**:571–582. [[PubMed](#)] [[Google Scholar](#)]

46. Saini N, Sikri P, Gupta H. Evaluation of the relative efficacy of autologous platelet-rich plasma in combination with β -tricalcium phosphate alloplast versus an alloplast alone in the treatment of human periodontal infrabony defects: a clinical and radiological study. *Indian J Dent Res.* 2011;**22**:107–115. doi: 10.4103/0970-9290.80008. [[PubMed](#)] [[CrossRef](#)] [[Google Scholar](#)]
47. Bharadwaj T, Kaushick BT, Jayakumar ND, Padmalatha O, Varghese S. Treatment of human periodontal infrabony defects with hydroxyapatite + β tricalcium phosphate bone graft alone and in combination with platelet rich plasma: a randomized clinical trial. *Indian J Dent Res.* 2011;**22**:505–510. doi: 10.4103/0970-9290.90278. [[PubMed](#)] [[CrossRef](#)] [[Google Scholar](#)]
48. Ozdemir B, Okte E. Treatment of intrabony defects with beta-tricalciumphosphate alone and in combination with platelet-rich plasma. *J Biomed Mater Res B Appl Biomater.* 2012;**100**:976–983. [[PubMed](#)] [[Google Scholar](#)]
49. Harnack L, Boedeker RH, Kurtulus I, Boehm S, Gonzales J, Meyle J. Use of platelet-rich plasma in periodontal surgery—a prospective randomised double blind clinical trial. *Clin Oral Invest.* 2009;**13**:179–187. doi: 10.1007/s00784-008-0223-7. [[PubMed](#)] [[CrossRef](#)] [[Google Scholar](#)]
50. Rodrigues SV, Acharya AB, Thakur SL. An evaluation of platelet-rich plasma without thrombin activation with or without anorganic bone mineral in the treatment of human periodontal intrabony defects. *Platelets.* 2011;**22**:353–360. doi: 10.3109/09537104.2011.552135. [[PubMed](#)] [[CrossRef](#)] [[Google Scholar](#)]
51. Döri F, Nikolidakis D, Húszár T, Arweiler NB, Gera I, Sculean A. Effect of platelet-rich plasma on the healing of intrabony defects treated with an enamel matrix protein derivative and a natural bone mineral. *J Clin Periodontol.* 2008;**35**:44–50. [[PubMed](#)] [[Google Scholar](#)]
52. Döri F, Kovács V, Arweiler NB, Huszár T, Gera I, Nikolidakis D, Sculean A. Effect of platelet-rich plasma on the healing of intrabony defects treated with an anorganic bovine bone mineral: a pilot study. *J Periodontol.* 2009;**80**:1599–1605. doi: 10.1902/jop.2009.090058. [[PubMed](#)] [[CrossRef](#)] [[Google Scholar](#)]
53. Piemontese M, Aspriello SD, Rubini C, Ferrante L, Procaccini M. Treatment of periodontal intrabony defects with demineralized freeze-dried bone allograft in combination with platelet-rich plasma: a comparative clinical trial. *J Periodontol.* 2008;**79**:802–810. doi: 10.1902/jop.2008.070436. [[PubMed](#)] [[CrossRef](#)] [[Google Scholar](#)]
54. Keceli HG, Sengun D, Berberoğlu A, Karabulut E. Use of platelet gel with connective tissue grafts for root coverage: a randomized-controlled trial. *J Clin Periodontol.* 2008;**35**:255–262. [[PubMed](#)] [[Google Scholar](#)]
55. Garcia RV, Gabrielli MA, Hochuli-Vieira E, Spolidorio LC, Filho JG, Neto FA, de Cardoso LA, Shibli JA. Effect of platelet-rich plasma on peri-implant bone repair: A histologic study in dogs. *J Oral Implantol.* 2010;**36**:281–290. doi: 10.1563/AAID-JOI-D-09-00056. [[PubMed](#)] [[CrossRef](#)] [[Google Scholar](#)]
56. Daif ET. Effect of autologous platelet-rich plasma on bone regeneration in mandibular fractures. *Dent Traumatol.* in press. [[PubMed](#)]
57. Wojtowicz A, Chaberek S, Urbanowska E, Ostrowski K. Comparison of efficiency of platelet rich plasma, hematopoieic stem cells and bone marrow in augmentation of mandibular bone defects. *NY State Dent J.* 2007;**73**:41–45. [[PubMed](#)] [[Google Scholar](#)]
58. Esposito M, Grusovin MG, Rees J, Karasoulos D, Felice P, Alissa R, Worthington HV, Coulthard P. Interventions for replacing missing teeth: augmentation procedures of the maxillary sinus. *Cochrane Database Syst Rev.* 2010;**17** CD008397. [[PubMed](#)] [[Google Scholar](#)]
59. Khairy NM, Shendy EE, Askar NA, El-Rouby DH. Effect of platelet rich plasma on bone regeneration in maxillary sinus augmentation (randomized clinical trial) *Int J Oral Maxillofac Surg.* in press. [[PubMed](#)]
60. Poeschl PW, Ziya-Ghazvini F, Schicho K, Buchta C, Moser D, Seemann R, Ewers R, Schopper C. Application of platelet-rich plasma for enhanced bone regeneration in grafted sinus. *J Oral Maxillofac Surg.* 2012;**70**:657–664. doi: 10.1016/j.joms.2011.04.027. [[PubMed](#)] [[CrossRef](#)] [[Google Scholar](#)]
61. Cabbar F, Güler N, Kürkcü M, Işeri U, Sençift K. The effect of bovine bone graft with or without platelet-rich plasma on maxillary sinus floor augmentation. *J Oral Maxillofac Surg.* 2011;**69**:2537–2547. doi: 10.1016/j.joms.2011.03.040. [[PubMed](#)] [[CrossRef](#)] [[Google Scholar](#)]
62. Anitua EA. Enhancement of osseointegration by generating a dynamic implant surface. *J Oral Implantol.* 2006;**32**:72–76. doi: 10.1563/736.1. [[PubMed](#)] [[CrossRef](#)] [[Google Scholar](#)]
63. Gentile P, Bottini DJ, Spallone D, Curcio BC, Cervelli V. Application of platelet-rich plasma in maxillofacial surgery: clinical evaluation. *J Craniofac Surg.* 2010;**21**:900–904. doi: 10.1097/SCS.0b013e3181d878e9. [[PubMed](#)] [[CrossRef](#)] [[Google Scholar](#)]
64. Anand U, Mehta DS. Evaluation of immediately loaded dental implants bioactivated with platelet-rich plasma placed in the mandibular posterior region: a clinico-radiographic study. *Indian Soc Periodontol.* 2012;**16**:89–95. doi: 10.4103/0972-124X.94612. [[PMC free article](#)] [[PubMed](#)] [[CrossRef](#)] [[Google Scholar](#)]
65. Markiewicz MR, Margaroni JE 3rd, Campbell JH, Aguirre A. Bisphosphonate-associated osteonecrosis of the jaws: a review of current knowledge. *J Am Dent Assoc.* 2005;**136**:1669–1674. [[PubMed](#)] [[Google Scholar](#)]
66. Yin G, Bai Y, Luo E. Angiogenic suppression of osteoclasts may play a role in developing bisphosphonate-related osteonecrosis of the jaw. *Med Hypotheses.* 2011;**76**:347–349. doi: 10.1016/j.mehy.2010.10.036. [[PubMed](#)] [[CrossRef](#)] [[Google Scholar](#)]
67. Advisory Task Force on Bisphosphonate-Related Osteonecrosis of the Jaws. American Association of Oral and Maxillofacial Surgeons position paper on bisphosphonate-related osteonecrosis of the jaws. *J Oral Maxillofac Surg.* 2007;**65**:369–376. [[PubMed](#)] [[Google Scholar](#)]
68. Montebugnoli L, Felicetti L, Gissi DB, Pizzigallo A, Pelliccioni GA, Marchetti C. Bisphosphonate-associated osteonecrosis can be controlled by nonsurgical management. *Oral Surg Oral Med Oral Pathol Oral Radiol Endod.* 2007;**104**:473–477. doi: 10.1016/j.tripleo.2007.01.008. [[PubMed](#)] [[CrossRef](#)] [[Google Scholar](#)]
69. Sanchez AR, Sheridan PJ, Kupp LI. Is platelet-rich plasma the perfect enhancement factor? A current review. *Int J Oral Maxillofac Implants.* 2003;**18**:93–103. [[PubMed](#)] [[Google Scholar](#)]
70. Dugrillon A, Eichler H, Kern S, Kliiter H. Autologous concentrated platelet-rich plasma (cPRP) for local application in bone regeneration. *Int J Oral Maxillofac Surg.* 2002;**31**:615–619. doi: 10.1054/ijom.2002.0322. [[PubMed](#)] [[CrossRef](#)] [[Google Scholar](#)]
71. Landesberg R, Roy M, Glickman RS. Quantification of growth factors levels using a simplified method of platelet rich plasma gel preparation. *J Oral Maxillofac Surg.* 2000;**58**:297–300. doi: 10.1016/S0278-2391(00)90058-2. [[PubMed](#)] [[CrossRef](#)] [[Google Scholar](#)]
72. Martínez-González JM, Sánchez JC, Lafuente JCG, Campo Trapero J, Esparza Gómez GC, Seoane Lestón JM. Do ambulatory-use Platelet-Rich Plasma (PRP) concentrates present risks? *Medicina Oral.* 2002;**7**:375–390. [[PubMed](#)] [[Google Scholar](#)]

